


Posterior Approaches



PR.MATT.OLLIVIER

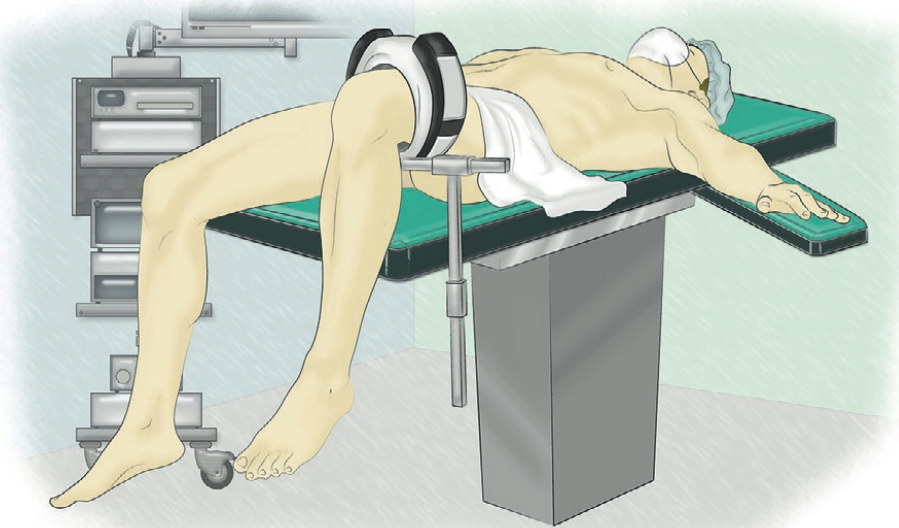
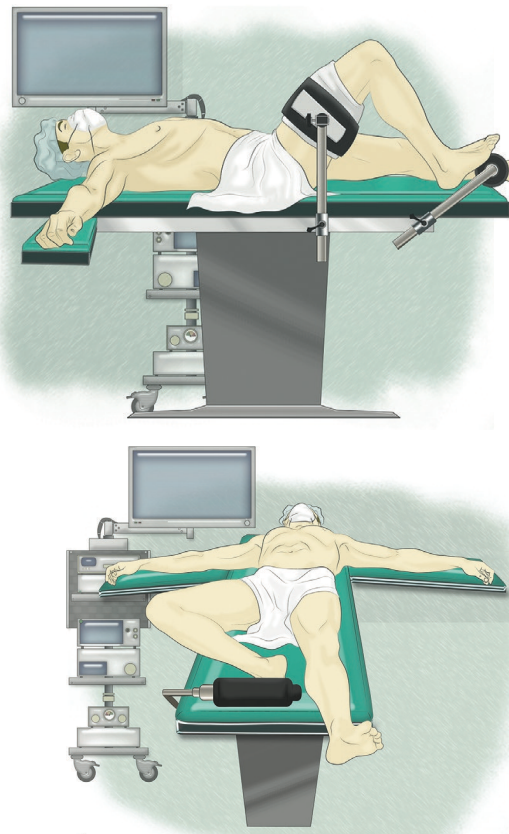
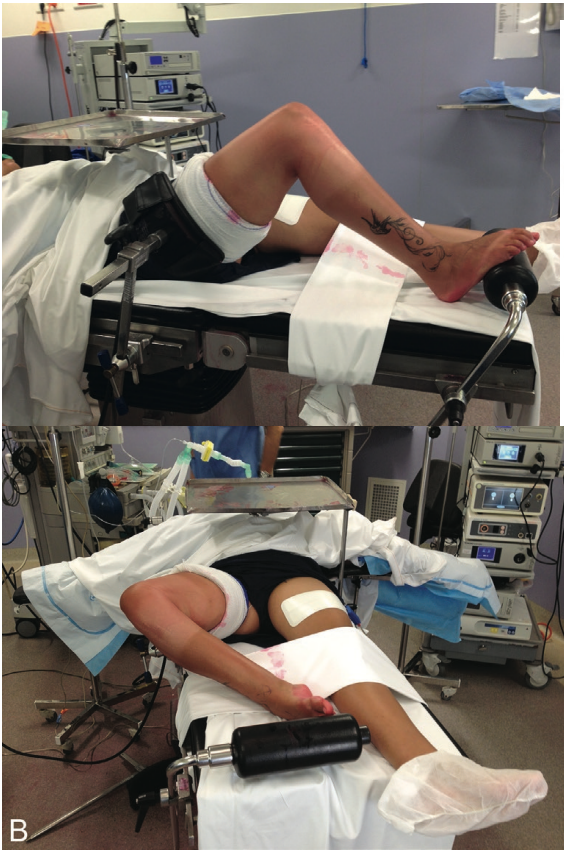


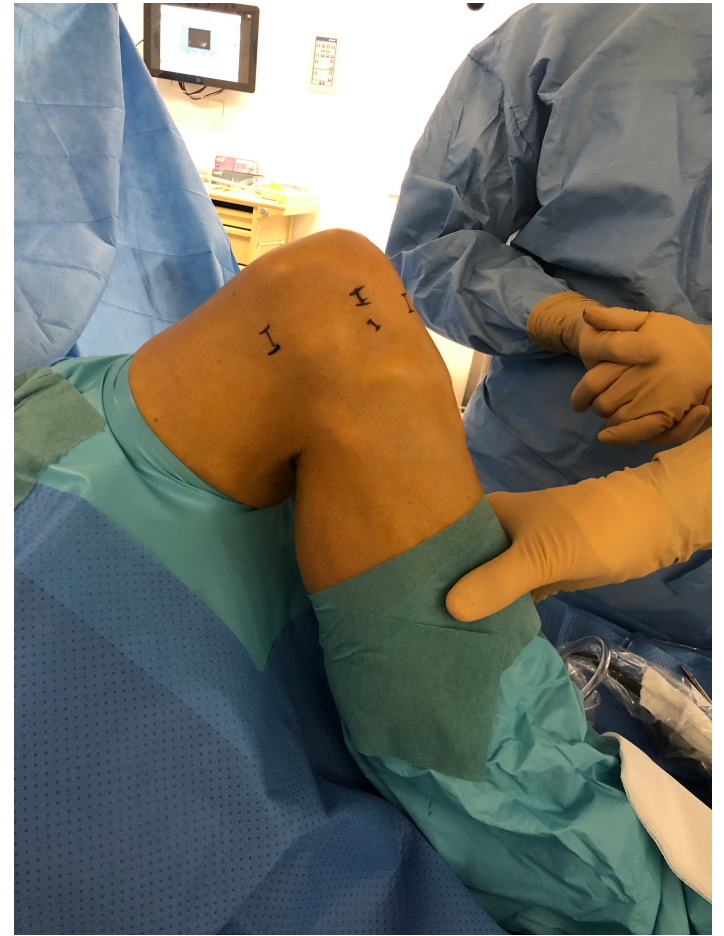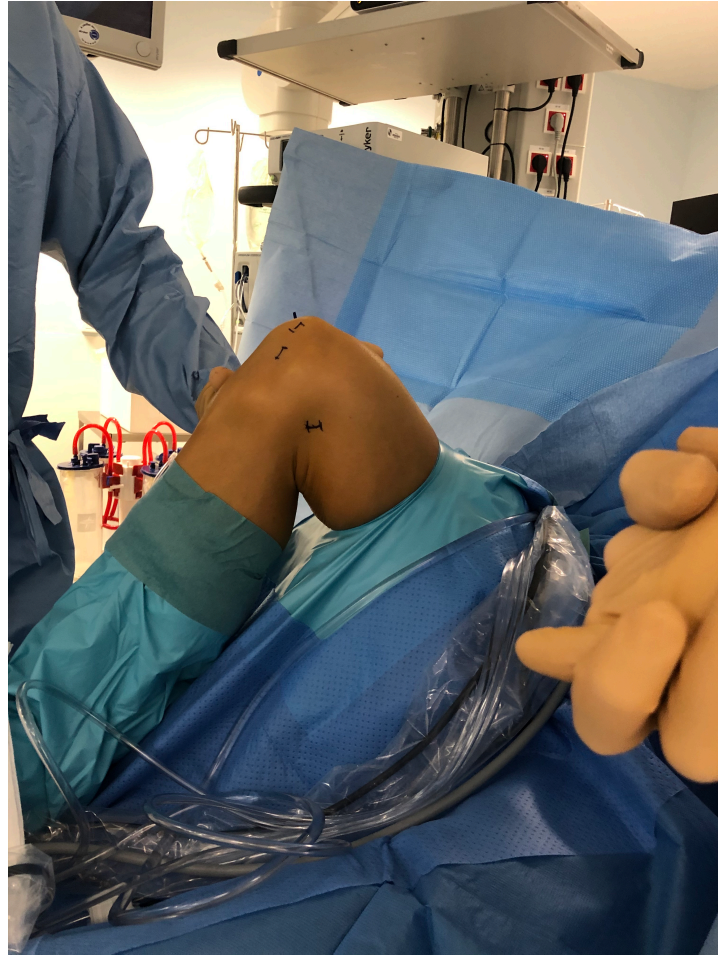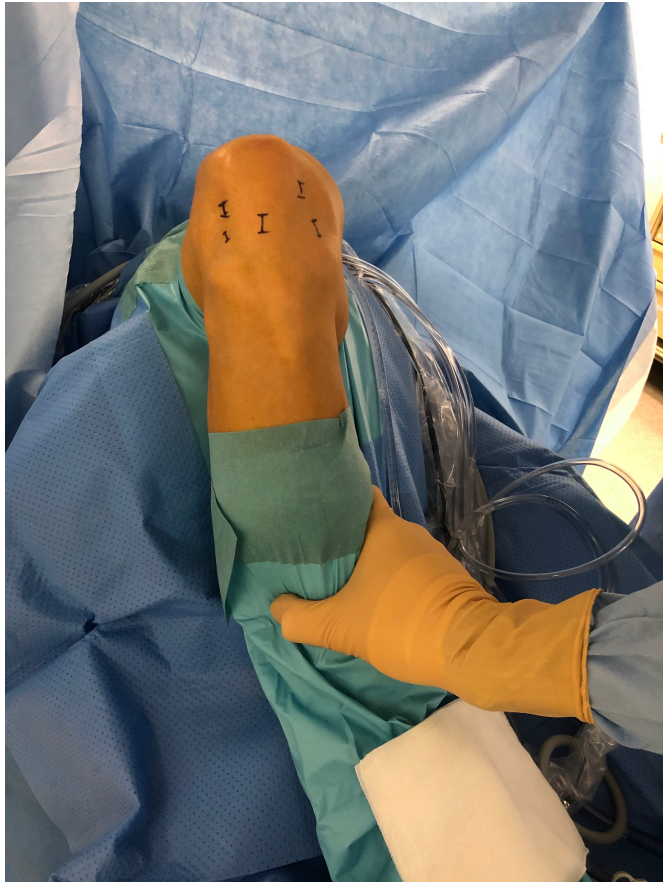Institut du Mouvement et de l'appareil Locomoteur





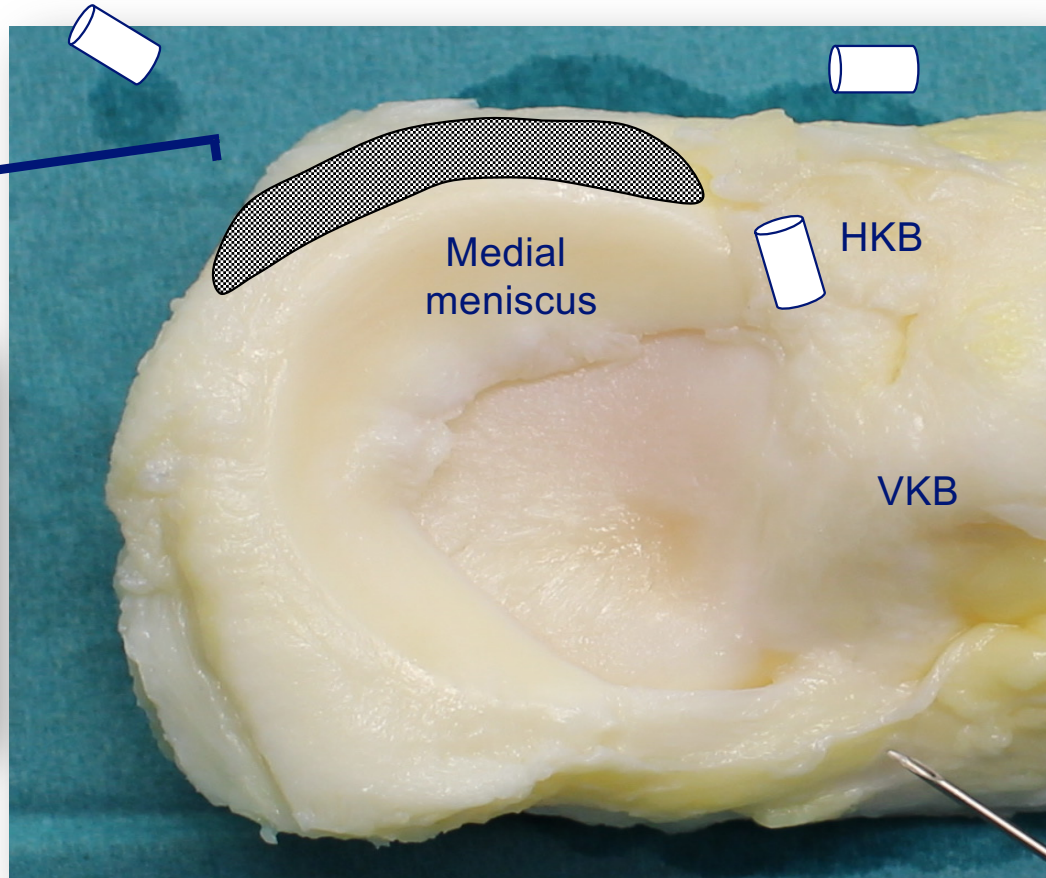
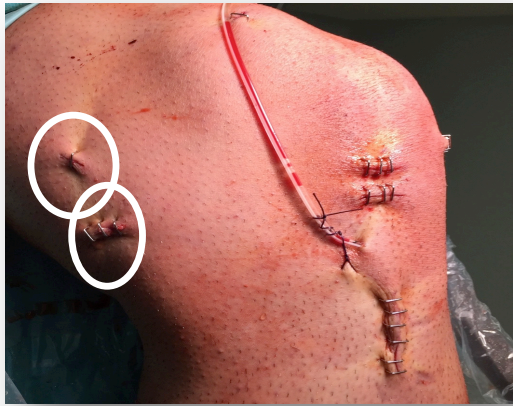Institut du Mouvement et de l'appareil Locomoteur





2. High PM portal

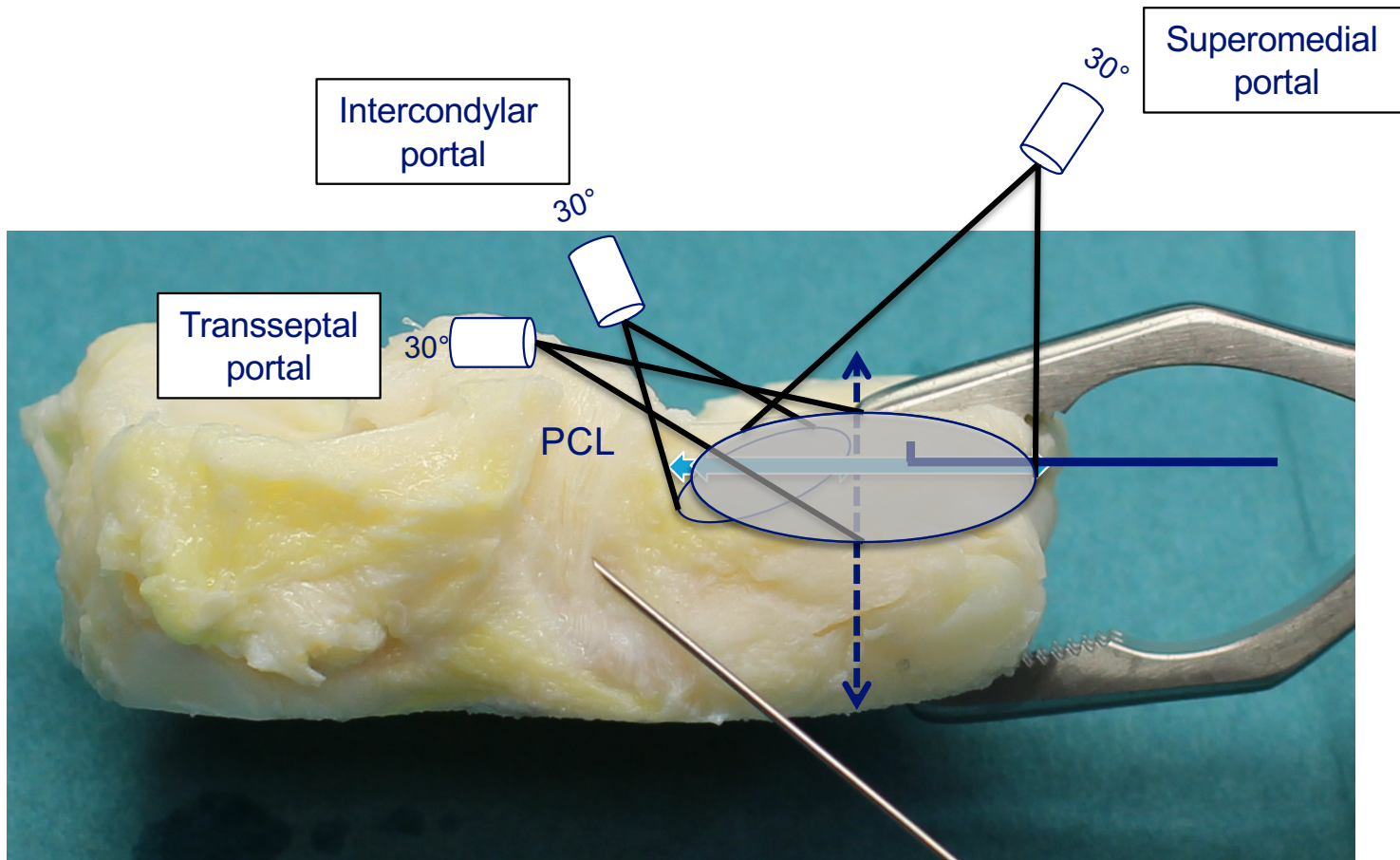
3. Low PM portal



4. Transseptal portal

1. Intercondylar portal – Gillquist (trans-notch)

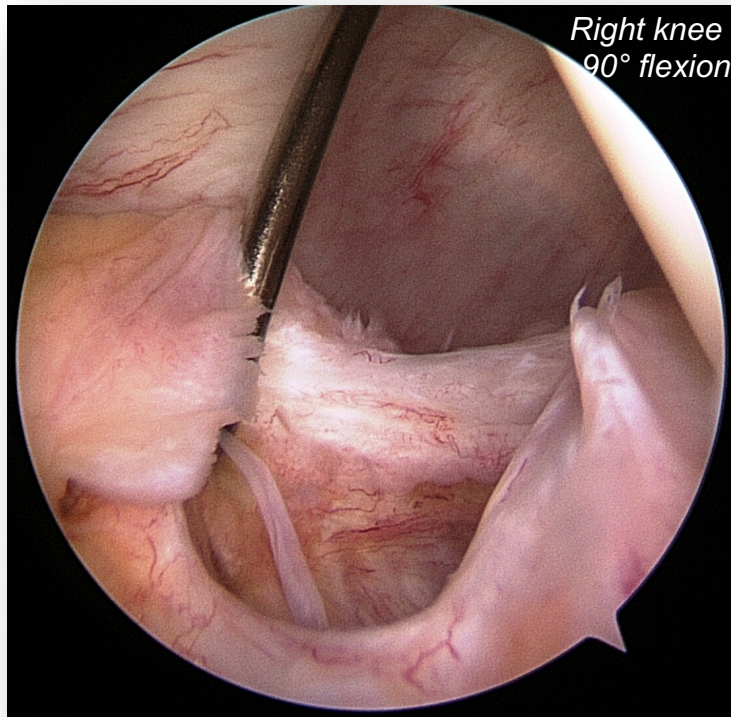
Courtesy R. SEIL



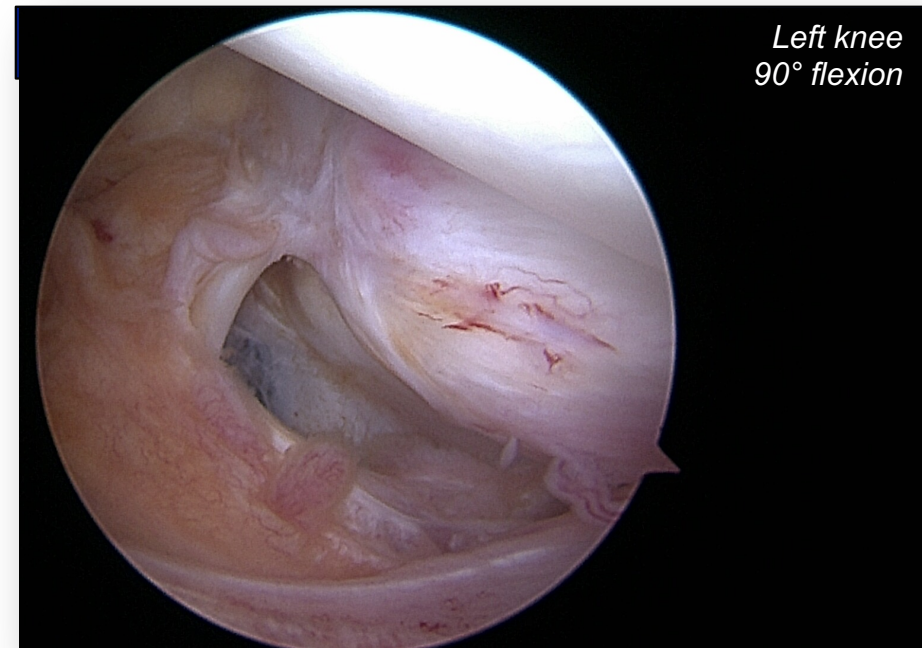
Courtesy R. SEIL

Arthroscopic diagnosis ?

Intercondylar view

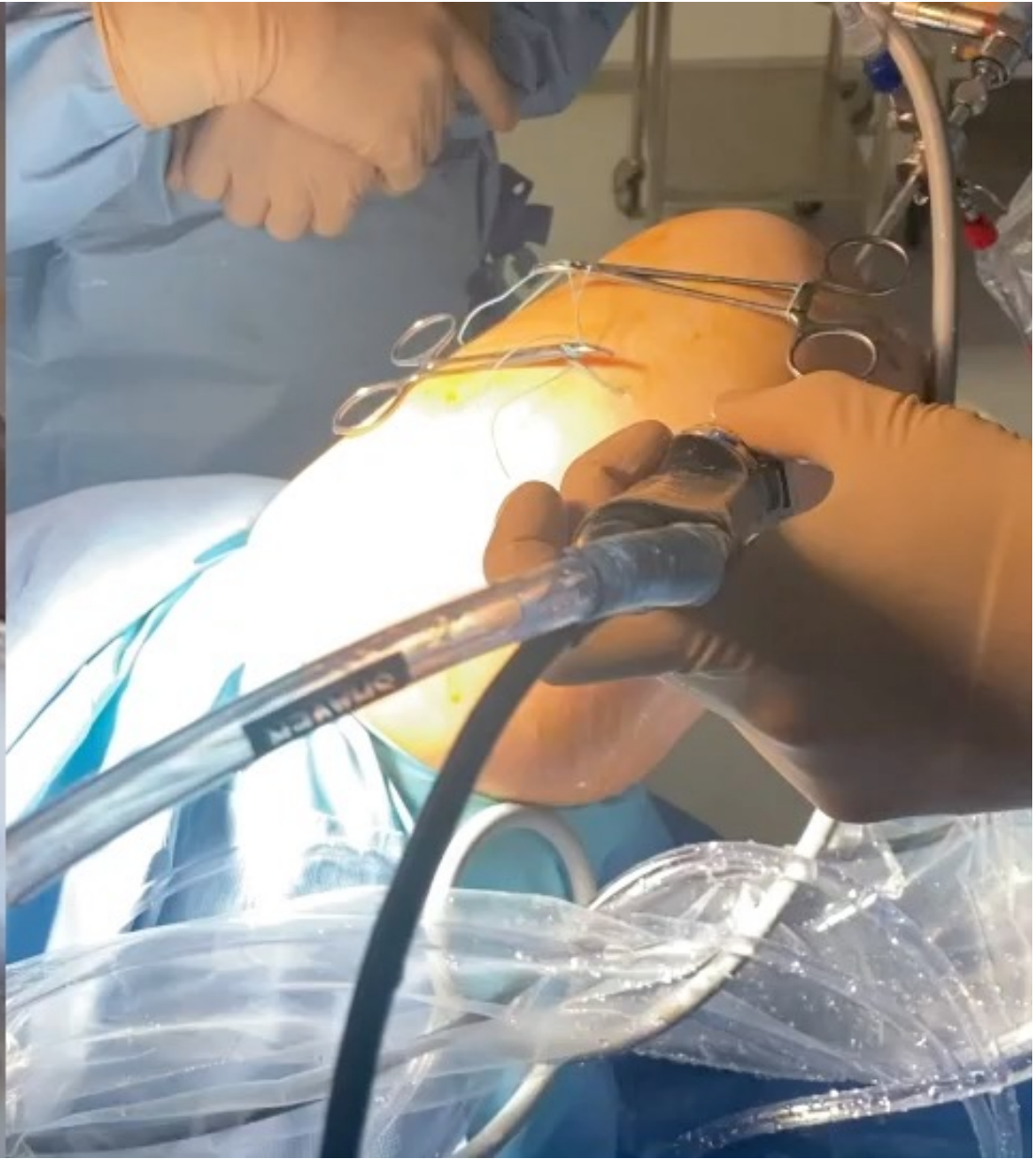

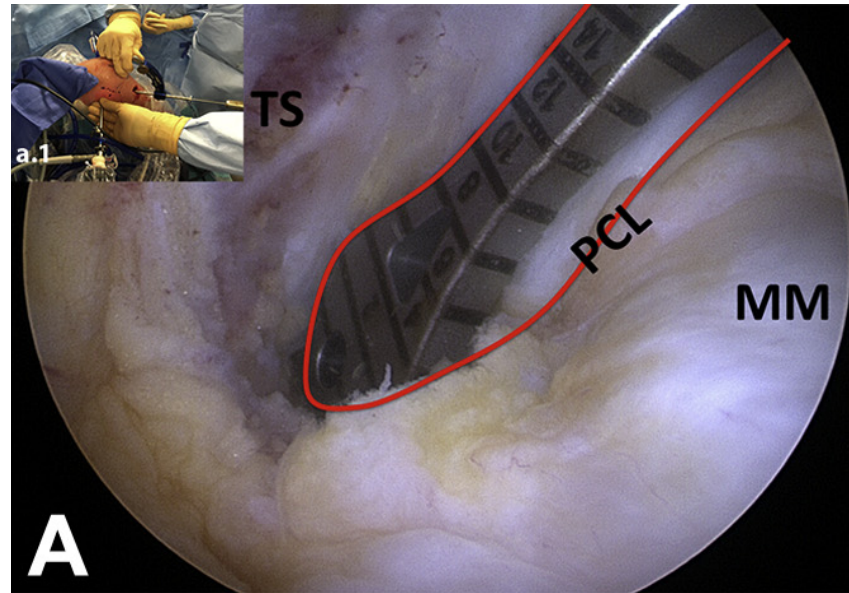
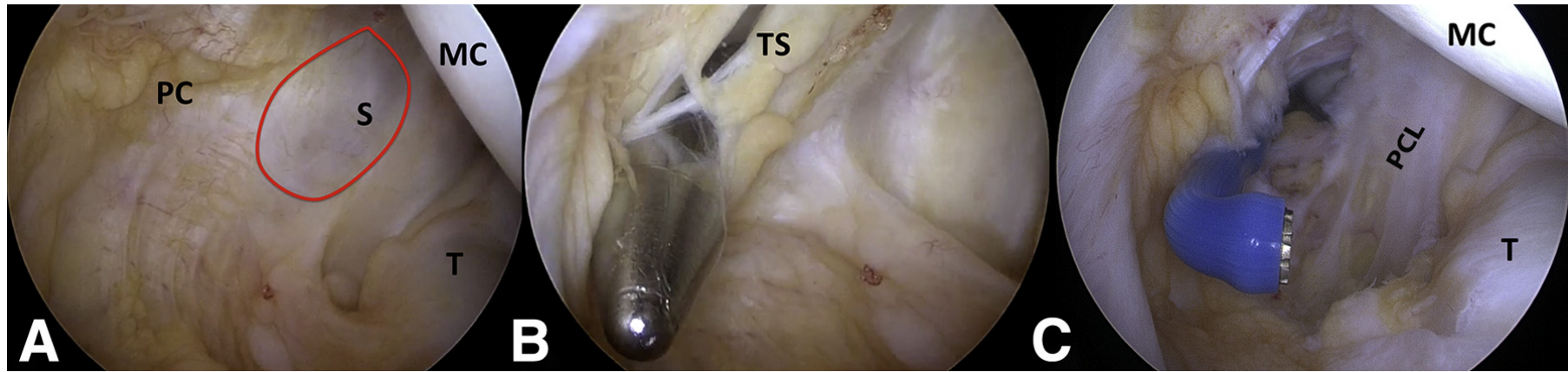
Posteromedial view

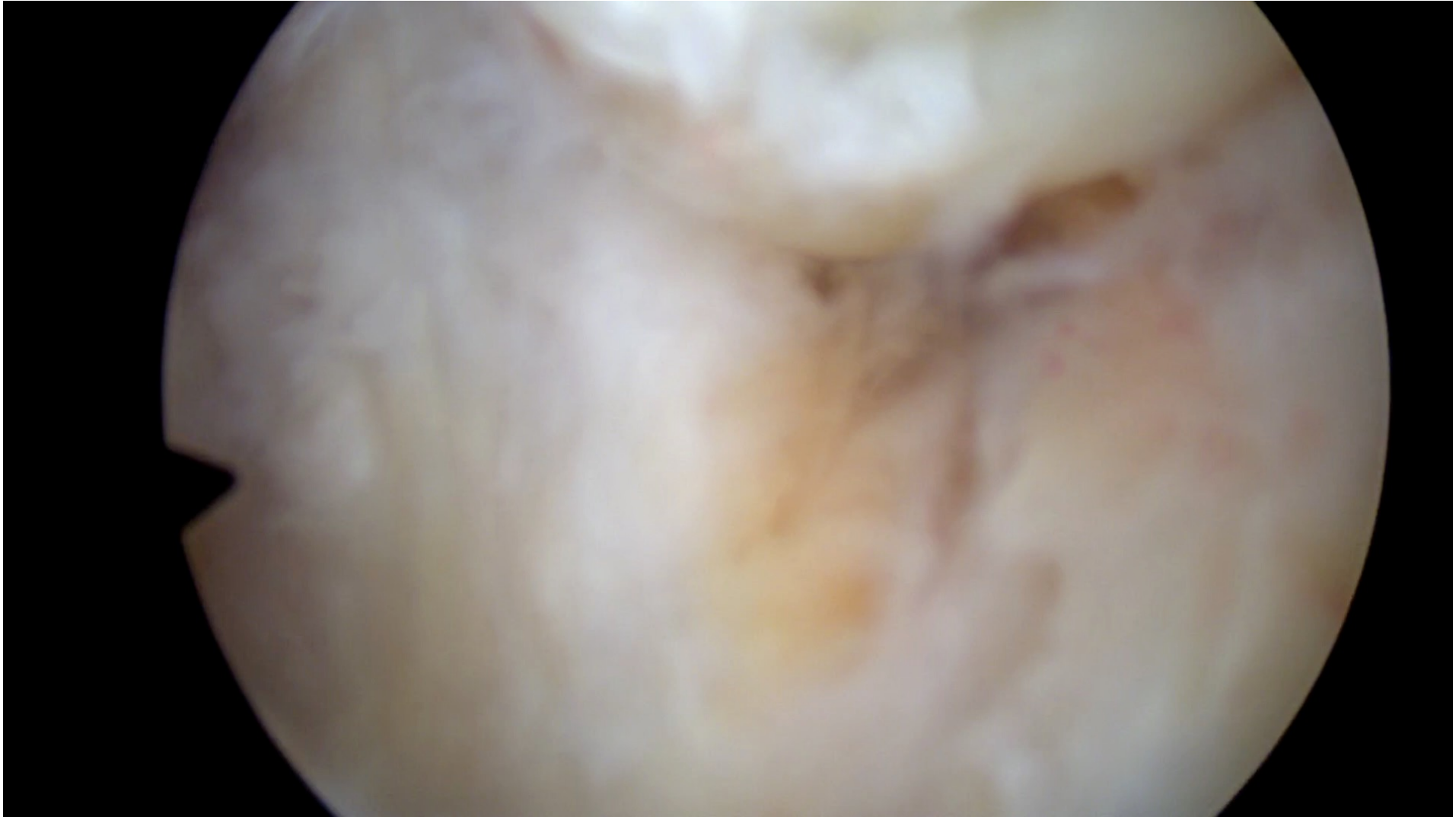

Courtesy Romain Seil

No healing without repair !









THANKS !

Matthieu.ollivier@ap-hm.fr

